

Study of foramen openings and their concurrence with root apexes

Estudo das aberturas foraminais e suas coincidências com os ápices radiculares

Sandra Maria Alves SAYÃO MAIA*
Ana Paula Peres COSTA**
Ana Tereza de Albuquerque LEMOS**
Valeska Rodrigues Jacob TORRÃO**
Ana Virginia Silva VILELA**

Correspondence:

Sandra Maria Alves Sayão Maia
Faculty of Dentistry of the State of Pernambuco
General Newton Cavalcanti Av., 1650 – Tabatinga – Camaragibe – PE
CEP 54753-220
E-mail: ssayao@uol.com.br

* Assistant professor with a Ph.D. from the Faculty of Dentistry of the State University of Pernambuco.

** 10th period students from the Faculty of Dentistry of the State University of Pernambuco.

Recebido em 31/1/05. Aceito em 2/3/05.

Keywords:

apical foramen; root apex;
topographic placing;
dental anatomy.

Abstract

The present study is aimed at evaluating the anatomic concurrence between foramen openings and root apexes of 247 upper and lower permanent human molar canals, the distance between these structures, the instrument that best fits into the root canal, as well as the direction of foramen deviation. Sixty-four of the canals were partially impenetrable and were discarded. The findings showed that 39.9% of the root canals studied had their apical foramen concurrent with their root apexes and 60.1% did not. Clinicians must be made aware of this important anatomical detail, which could be indispensable for successful endodontic treatment.

Palavras-chave:
forame apical; ápice radicular; localização topográfica; anatomia dentária.

Resumo

O objetivo da presente pesquisa foi avaliar a coincidência anatômica entre as aberturas foraminais e os ápices radiculares de 247 canais de molares humanos permanentes superiores e inferiores, a distância entre essas estruturas, a direção para a qual ocorreu o desvio do forame, bem como a lima que melhor se ajustou ao canal. Sessenta e quatro canais encontravam-se parcialmente impenetráveis, sendo descartados do estudo. Os resultados demonstraram que 39,9% dos canais radiculares estudados tiveram seus forames apicais coincidentes com os ápices radiculares, e 60,1% não. Os dados encontrados alertam para esse importante detalhe anatômico, que pode ser fundamental para o sucesso do tratamento endodôntico.

Introduction

Clinical problems that can arise from endodontic practices are due to variations in the apexes of root canals, which are reflected in the various dentistry specialities, with anatomic and physiological knowledge being fundamental so as to the carrying out of a diagnosis and planning of the adequate treatment.

Bhaskar (1978) [1] affirmed that the locality and form of apical foramen could suffer alterations in teeth with functional influences. Migrating mesially, the tissues that penetrate the pulp through the apical foramen put on pressure, which results in the relocation of the original foramen, and explains the occurrence of apical openings in the lateral part of the apex, even when there is no curving of the root.

Burch and Hulen (1972) [2] studied 860 teeth to determine incidences of deflection of the foramen of anatomic apices and ascertained that 92.4% of all the larger foramen of all the teeth under study opened near the anatomic apex. The average distance between the foramen and the anatomic apex was 0.59cm.

Kuttler (1955) [4], who studied 402 apices of healthy teeth from corpses between the ages of 18 and 25, or more than 55 years of age, using an ocular micrometer, observed that the centre of the foramen comes away from the apical vertex with an increase in age. He also observed that the cementary cone does not follow the same tooth orientation, and also does not end in the apex vertex, deviating to one of its sides at a distance of 0.5mm, thus justifying a root canal in the referred to limit.

In accordance with Inou and Skinner (1985) [3] the ideal extent for the biomechanical preparation and filling of the root canal is 0.5 to 0.7mm to the side of the foramen, at the dental cementary joint, without damaging the adjoining periapical tissue. A definition by X-ray of this limit is extremely difficult,

as there is a chosen value of 0.5 to 1.00mm to be subtracted from the root length of the X-ray image.

Milano *et al.* (1983) [6] observed in "in vitro" research with 180 teeth that only 12.6% of the studied canals had a centric opening. The majority of the foramen (61.7%) deviated to the distal and its mid-way positions. For mesial and mid-way the deviation was 12.2%, for the buccal, the deviation was 8.8% and for lingual, 4.6%.

Tamse *et al.* (1988) [7] did a study with primary and secondary lower molars with the objective of correlating and placing the apex foramen in distal roots, with interpretation from clinical X-rays and after pulling, the true morphological positioning of the foramen. The placing was centric in 10 to 15% of the cases. The apex foramen was seen as being to the side of the apex of the clinical X-rays in 57.5%. This fact is related to the incidence of foramen in the buccal walls (10%) or lingual (7.5%), and, mainly, to the overlapping of the soft and hard tissues in the images of the canal and root apices in the clinical X-rays. According to them, 60% of the root canals that are interpreted by X-rays as being to the side of the apices, were actually seen on the distal surfaces of the roots.

Tamse *et al.* (1988) [7], on complementing their study, evaluated the distance of the foramen of the apex in distal roots of lower molars to compare clinical X-ray data after extraction and morphological measures. The difference between the true distance (morphological evaluation) and the measurements of clinical X-rays was 0,24mm ($p < 0.05$), confirming the effect caused by the overlapping of hard and soft tissues.

Wu *et al.* (2000) [9] affirm that the bringing of instrumentation to an end is not necessarily the same for vital and infected cases. But when it goes much beyond, or to the side, it negatively influences the

results. In spite of the 0.5 to 1.0mm to the side of the X-ray apex, commonly used to determine the length of the work necessary, it is only an estimate in an attempt to place the debris and filling near the apical foramen, and not beyond.

The objective of this present research was to evaluate in vitro, by the use of visual methods with a magnifying glass of 3.5X and a pachymetre, the concurrence or not between the foramen outlets and the root apexes in human molars. The distance between the emergence of apical foramen and root apexes, as well as the direction in which the foramen opening occurred were also measured when there was no concurrence as referred to above. The study went on to verify the filing that better adjusted to the interior of the canals studied.

Materials and methods

247 root canals of upper and lower permanent human molars of complete roots and apexes, completely formed, obtained from patients who use the State of Pernambuco public health services were used.

The specimens were disinfected with a sodium hypochlorite solution of 4.0 to 6.0% during 30 minutes and then left to dry and afterwards sectioned in the anatomic dental equator region with the use of carborundum disks. After wetting with a solution of sodium chlorite of 0.9% for 24 hours, the cathetometric work was begun, with endodontic filings type K, until they adjusted themselves within the canal, being visually seen in the apical foramen with the help of a 3.5X magnifying glass. In some cases, because of calcification, such a fact occurred. The concurrence or not of apical foramen with the apical root were analysed. When they were not coincident, a pachymetre was used to measure the existing distance between these structures, thus being able to see the direction of the deviation made by the apical foramen.

Results

Of the 247 studied canals, 64 were rejected because it was not possible to penetrate them with a file so as to be able to see the foramen emergence.

In this study, descriptive techniques were used through tables, including absolute distribution,

percentages and statistical measures, as well as graph illustrations. The statistical calculations were carried out on the Statistical Analysis System (SAS) programme, version 6.12, for microcomputers.

In tables 1 to 3, the deviation results as well as the direction and distance between the apical foramen and the root apical are presented. Table 4 shows the distribution of the files used. The results refer to the 183 canals that were penetrated.

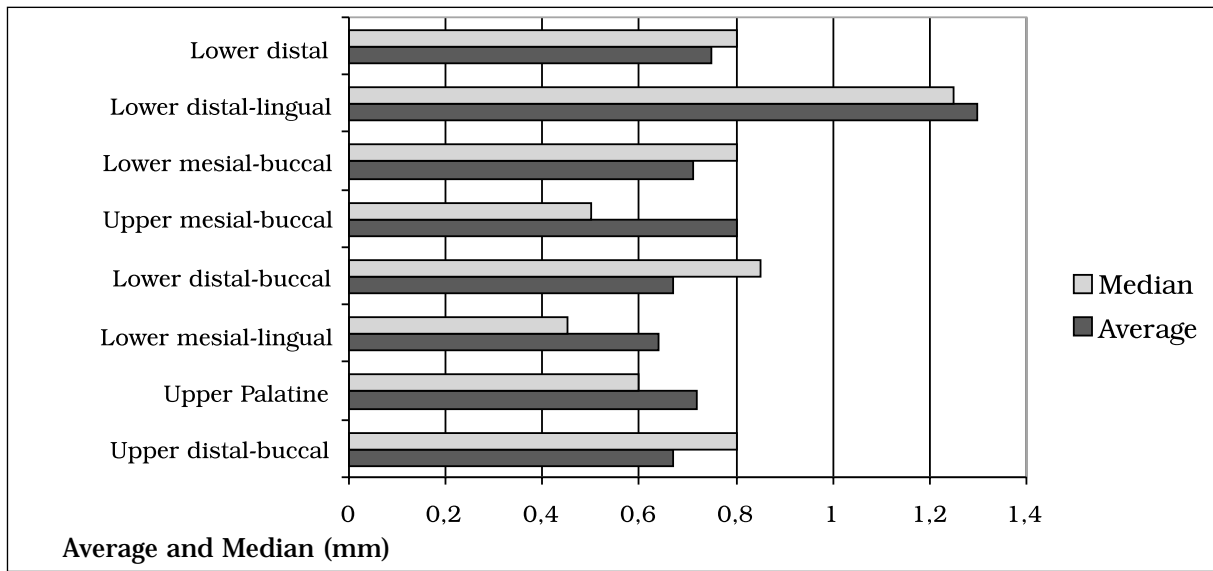
Table 1 – Distribution of data according to foramen positioning in relation to the apical root

Canal groups	Position of foramen					
	Central		Eccentric		Total	
	N	%	N	%	N	%
Upper mesial-buccal	8		13		21	100.0
Upper distal-buccal	8	38.1	13	61.9	21	100.0
Upper palatine	5	38.1	21	61.9	26	100.0
Lower mesial-buccal	19	19.2	18	80.0	37	100.0
Lower mesial-lingual	14	51.4	16	48.6	30	100.0
Lower distal-buccal	10	46.7	10	53.3	20	100.0
Lower distal-lingual	1	50.0	4	50.0	5	100.0
Lower distal	8	25.0	15	75.0	23	100.0
		34.8		65.2		
Total	73	39.9	110	60.1	183	100.0

Table 2 and graph 1 present the average, the median, the standard deviation and the co-efficient of the variation value of the deviation. The highest average and median occurred in distal-lingual canals of the lower molars. The differences as expressed through the co-efficient variation went from reasonable (48.9%) to highly elevated (113.87%).

Table 2 – Statistics of the deviation values

Canal groups	Statistics			
	Average (mm)	Median (mm)	Standard deviation (mm)	CV* (%)
Upper mesial-buccal	0.80	0.50	1.01	113.87
Upper distal-buccal	0.67	0.80	0.35	52.61
Upper palatine	0.72	0.60	0.35	48.90
Lower mesial-buccal	0.71	0.80	0.42	58.66
Lower mesial-lingual	0.64	0.45	0.61	95.75
Lower distal-buccal	0.67	0.85	0.31	48.26
Lower distal-lingual	1.30	1.25	0.68	52.17
Lower distal	0.75	0.80	0.45	59.97



Graph 1 – Average and median of the deviation value of the canal groups

Table 3 – Topography placing of foramen in apical region

Canal groups	Direction													
	Central		Distal		Mesial		Palatine		Buccal		Lingual		Total	
	N	%	N	%	N	%	N	%	N	%	N	%	N	%
Upper mesial-buccal	8	38.1	6	28.6	2	9.5	5	23.8	-	-	-	-	21	100.0
Upper distal-buccal	8	38.1	6	28.6	2	9.5	2	9.5	333	14.3	-	-	21	100.0
Upper palatine	5	19.2	11	42.3	1	3.9	4	15.4	5	19.2	-	-	26	100.0
Lower mesial-buccal	19	51.4	2	5.4	5	13.5	-	-	2	5.4	9	24.	37	100.0
Lower mesial-lingual	14	46.7	3	10.0	3	10.0	-	-	8	26.7	2	3	30	100.0
Lower distal-buccal	10	50.0	6	30.0	2	10.0	-	-	2	10.0	-	6.6	20	100.0
Lower distal-lingual	1	20.0	1	20.0	1	20.0	-	-	1	20.0	1	-	5	100.0
Lower distal	8	34.8	8	34.8	4	17.4	-	-	1	4.3	2	20.	23	100.0
											0	8.7		
Total	73	39.9	43	23.5	20	10.9	11	6.0	22	12.0	14	7.7		100.0

As to the number of files used, which better adjusted themselves in the canals studied, table 4 shows that the highest percentages were numbers 6 and 8, that is, 0.06mm and 0.08mm respectively.

Table 4 – Distribution of files used

Files	N	%
06	57	31.2
08	67	36.6
10	30	16.4
15	24	13.2
20	2	1.1
25	1	0.5
30	1	0.5
35	1	0.5
Total	183	100.0

Discussion

The authors are unanimous in affirming that the junction of the dental cementary root canal is the ideal limit for the instrumentation and filling of the same, and that it is extremely difficult to mark the exact position of this point, as it is highly variable.

Many different experiments tried to establish a distance of the apical foramen to the root apex by using teeth which had been extracted (Kuttler, 1955 [4]; Burch and Hulen, 1972 [2]), or by comparing them to their X-ray evaluations (Tamse *et al.*, 1988 [7], Kaffe *et al.*, 1988 [8]).

As to the topographical positioning of the apical foramen, Kuttler (1955) [4], Burch and Hulen (1972) [2], Milano *et al.* (1983) [6].

Tamse *et al.* (1988) [7] and Kaffe *et al.* (1988) [8] all verified that it is highly variable. It could be

seen in mesial, distal, buccal and lingual or central. In collaboration with their opinion, the present study verified that there was a deviation of the apical foramen in 110 of the 183 canals in which it was possible to use a file.

Burch and Hulen (1972) [2] affirmed that 92.4% of all the apical foramen of the teeth under study opened near to the anatomic foramen. Tamse *et al.* (1988) [7], although having found less expressive results (65%), they also agreed that the majority of foramen emerge in an eccentric position to the apical root. In agreement with the results of this study, of the 183 canals studied, the opening of the apical foramen was central in only 39.9%. In the majority of the cases, 60.1%, the apical foramen was not found at the root apex. Seventy-four of the canals were impenetrable.

Burch and Hulen (1972) [2] found, in all types of teeth, an average distance of 0.59mm from the apical foramen to the root apex. Tamse *et al.* (1988) [7], on evaluating, in morphological terms and through X-rays, the lower molars, verified an average distance of 0.24mm. This was the lowest average obtained. However, Guiterrez and Aguayo (apud Malueg *et al.*, 1996 [5]) showed that the distance from the anatomical apex varied from 0.2 to nearly 4.0 mm, which agrees with the results obtained in this study.

The findings of this study are also in agreement with those of Milano *et al.* (1983) [6], who observed in an experiment with all types of teeth, that the major deviation tendency fell more to the distal side.

It is important to consider that the Brazilian population, being composed of three ethnic groups, could contribute to the diversity of data obtained in this study.

Conclusion

Taking into consideration all the results of this study, it is licit to conclude that:

- a) the topographical placing of the foramen is largely variable, been present in mesial, distal, buccal, lingual and centre;
- b) the opening of the apical foramen was central in 39.9% of the 183 canals studied; in 60.1 % the apical foramen was not found at the root apex;
- c) the distance of the apical foramen to the root apex of all the canals varied from 0.1 mm to 4.0 mm;
- d) the average distance of the apical foramen in relation to the root apexes of all the

groups of canals under study, varied from 0.64 to 1.3 mm. The greatest average found among the distal-lingual canals of lower molars was 1.33mm;

- e) the most frequent deviation direction of the apical foramen fell to the distal side, in 23.5% of all the canals evaluated. The lowest average direction found was the palatine, represented in 6.0% of the canals;
- f) the most used file was number 8;
- g) latter studies should be done in order to enrich this information concerning the inherent variations in the apical region of root canals.

References

1. Bhaskar S N. *Histologia e embriologia oral de Urban*. 8. ed. São Paulo: Artes Médicas; 1978. 484 p.
2. Burch J G, Hulen S. The relationship of the apical foramen to the anatomic apex of the tooth root. *Oral Surg. Oral Med. Oral Pathol.* 1972 Aug.; 34(2): 262-8.
3. Inoue N, Skinner D H. A simple and accurate way of measurement root canal length. *J. Endod.* 1985 Oct.; 11(10).
4. Kuttler Y. Microscopic investigation of root apex. *JADA* 1955; 50: 544-52.
5. Malueg L A, Wilcox L R, Johnson W. Examination of external apical root resorption with scanning electron microscopy. *Oral Surg. Oral Med. Oral Pathol.* 1996 Jan.; 82(1): 89-93.
6. Milano N F, Werner S M, Kapczinski M. Localização do forame principal. *RGO* 1983 jul./set.; 31(3): 220-4.
7. Tamse A, Littner M M, Kaffe I *et al.* Morphological and radiographic study of the apical foramen in distal roots of mandibular molars. Part I. The location of the apical foramen on various root aspects. *Int. Endod. J.* 1988; 21(3): 205-10.
8. Kaffe I, Littner M M *et al.* Morphological and radiographic study of the apical foramen in distal roots of mandibular molars. Part II. The distance between the foramen and the root end. *Int. Endod. J.* 1988; 21(3): 211-7.
9. Wu M K, Wesselink P R, Walton R E. Apical terminus location of root canal treatment procedures. *Oral Surg. Oral Med. Oral Pathol.* 2000 Jan.; 89(1): 99-103.