

*Artigo Original de Pesquisa*

## Comparative histological study between MTA and Portland cement

## Estudo histológico comparativo entre MTA e cimento Portland

Cristina de Jesus REISS-ARAÚJO\*  
Kércya da Silva PAIM\*\*  
Marcelo de Azevedo RIOS\*\*\*  
Diana Santana de ALBUQUERQUE\*\*\*\*  
Flares BARATTO FILHO\*\*\*\*\*  
José Roberto VANNI\*\*\*\*\*

**Correspondence:**

Cristina de Jesus Reiss-Araújo  
Av. Gonçalo Rollemberg Leite, 2.319 – Ed. Port Spain – ap. 1.103  
Bairro Suissa – Aracaju – SE – Postcode 49045-280  
E-mail: endocris@uefs.br

\* Ph.D. Univeristy State of Feira de Santana (UEFS).  
\*\* M.Sc. Univeristy State of Feira de Santana (UEFS).  
\*\*\* M.Sc. Univeristy State of Feira de Santana (UEFS).  
\*\*\*\* Ph.D. Univeristy State of Pernambuco (FOP).  
\*\*\*\*\* Ph.D. Positivo University (UP-PR).  
\*\*\*\*\* Ph.D. University of CEOM-Uningá, Passo Fundo (RS).

**Recebido em 12/12/06. Aceito em 24/11/07.**

**Keywords:**

MTA; perfuration; Portland cement.

### Abstract

**Introduction:** Several studies have demonstrated the effectiveness of MTA as a promising material in Dentistry. There is a possibility that the Portland cement may provide the same results of MTA due to the similar composition of both materials. **Objective:** comparing the MTA and Portland cement by means of histological observation. **Material and methods:** Two groups of five wistar rats (*Rattus norvegicus*) each were submitted to surgery at the filtrum area for insertion of a polyethylene tube containing MTA (left side) and Portland cement (right side). After flap closure, the animals were placed in isolation and two different periods (2 and 12 weeks) were selected to sacrifice the animals. Blocks were obtained from the animals, stored in 10% formalin solution and submitted to histological preparation. All blocks were observed under a light microscope. **Results:** The results showed that the MTA yielded a less intense histological reaction than the Portland cement in

2-week period. In the 12-week period, the histological results were very similar for both cements. **Conclusion:** Utilization of the Portland cement in Dentistry can be considered.

#### Palavras-chave:

MTA; perfuração; cimento Portland.

### Resumo

**Introdução:** Muitos estudos têm demonstrado a efetividade do MTA como um material promissor na Odontologia. Existe a possibilidade de o cimento Portland proporcionar os mesmos resultados do MTA em função da composição similar de ambos os materiais. **Objetivo:** Comparar o MTA e o cimento Portland de acordo com os dados da observação histológica. **Material e métodos:** Dois grupos de cinco ratos Wistar (*Ratus norvegicus*) foram submetidos à cirurgia na região de filtro para inserção de tubos de polietileno contendo MTA (lado esquerdo) e cimento Portland (lado direito). Após a sutura, os animais foram isolados por dois diferentes períodos (2 e 12 semanas) e sacrificados na seqüência. As peças foram extraídas dos animais, fixadas em formol a 10% e submetidas ao preparo histológico. Todas as peças foram observadas em microscópio. **Resultados:** os resultados mostraram que o MTA induziu uma reação inflamatória menor que o cimento Portland, sendo os resultados histológicos similares entre os cimentos. **Conclusão:** A utilização do cimento Portland pode ser considerada.

### Introduction

There has been a remarkable evolution in Dentistry over the years, especially as regards the new materials introduced in the dental market. The professionals are not sure about many of these materials and therefore do not employ them because of the lack of studies conducted before they are introduced. The update of the market in relation to the new materials should be constant in all specialties, as well as studies providing data on the product we intend to use.

The MTA is a new material that may be employed for several purposes such as pulp capping, pulpotomy, endodontic surgery as retrograde filling material, and as a sealant for furcation or root perforations. It is highly biocompatible, presents excellent sealing properties and a good performance in moisture and induces the formation of a hard tissue barrier due to its high pH (similarly to the application of calcium hydroxide on the dental pulp), therefore displaying excellent characteristics for utilization [6, 10, 11]. It comprises a powder (white or gray), which is constituted by hydrophilic particles that are solidified by water, thus the contact between the material and the periapical fluids stimulates the initiation of chemical reactions for setting. Its main components are tricalcium silicate, tricalcium aluminate, tricalcium oxide and silicate oxide, besides other mineral oxides (not specified by the authors) and the bismuth oxide added to provide radiopacity to the material [1, 5].

According to Torabinejad *et al.* (1995) [9], the main molecules found in MTA are calcium and phosphate ions. Since these elements are also the main components of the dental hard tissues, this may contribute to its biological compatibility with the surrounding tissues. The material is divided in calcium oxide, which comprises small crystals, and calcium phosphate, which presents an amorphous structure of granular appearance. The prisms are composed by an average of 87% calcium, 2.47% silica, and oxygen. The amorphous structure contains 49% phosphate, 2% carbon, 3% chloride and 6% silica. The chemical composition, pH, radiopacity, setting time, solubility and resistance to compression of MTA were also addressed in this study.

Estrela *et al.* (2000) [2] conducted a study with a view to investigate the antimicrobial action of the Mineral Trioxide Aggregate, Portland cement, calcium hydroxide paste, Sealapex and Dycal. Moreover, the authors analyzed the chemical constituents of MTA and the Portland cement. The antimicrobial activity of the calcium hydroxide paste was shown to be higher than all other materials for all microorganisms studied. The Portland cement contains the same chemical components as MTA, with the exception that MTA also contains bismuth.

Concerning the physical-chemical properties, studies addressing the properties of the Portland cement are employed as a reference, since even the MTA's manufacturer recognizes the presence of the

Portland cement on its composition and also because some scientific studies have demonstrated that both MTA and Portland cement present the same composition and mechanism of action (8).

Holland *et al.* (2001) [3] evaluated the reaction of the subcutaneous tissue of rats to the implantation of dentin tubes filled with mineral trioxide aggregate, Portland cement or calcium hydroxide. The results were similar for all materials analyzed. For that reason, the authors believed that the mechanism of action of these materials may be similar.

Any material employed for dental purposes should necessarily be biocompatible. Therefore, several *ex vivo* and *in vivo* analyses of the materials are required before they are employed in the daily clinical practice. For that reason, the aim of this study was to histologically evaluate the Mineral Trioxide Aggregate and compare it to the Portland cement in rats.

## Material and methods

### Sample and research technique

The present study comprised a light microscopy evaluation of the alterations affecting the connective tissue of the filtrum area of rats (which corresponds to the oral vestibule in mankind) after insertion of two types of cement: the Mineral Trioxide Aggregate (MTA) – PROROOT® (Dentsply, Tulsa Dental – USA) and the Portland cement® (Cimento Zebu – Companhia de Cimento Atol – Brazil), CP2z32.

A total of ten male rats of the species *Rattus norvegicus*, wistar strain, weighing about 313.73g and characterized as young adults (approximately three months of age) were employed in this study. All animals were submitted to surgery in the same day. The employment of animals in the present study was authorized by the Ethics Committee of the State University of Feira de Santana.

The animals were deprived from water two hours before surgery and from food six hours before surgery. Anesthesia was performed as follows: 1% Acepromazin 0.3ml/100g/PV (trade name 1% Acepran, Univet) was applied as a pre-anesthetic drug, since it is neuroplegic and tranquilizer and therefore increases the response of the animals to the general anesthesia. After a 10-min interval, Ketamine 0.2ml/100g/PV (trade name Dopalen, AgribRANDS do Brasil LTDA) was applied as a general anesthetic agent.

The surgery comprised removal of a flap from each side of the filtrum area of each animal with a blade n. 11 (Surgiplast). Both the Portland cement and MTA were prepared with sterile saline solution and immediately after preparation they were placed

in polyethylene tubes (less than 1.3m in diameter, Biojet) measuring approximately 1 to 2mm in width, which were inserted in the flaps. The MTA was always inserted at the left side and the Portland cement at the right side. Suture was performed with absorbable suture (Catgut 3.0 – Somer Ville). The animals were divided in two study groups:

Group I – five animals, sacrificed two weeks after surgery;

Group II – five animals, sacrificed twelve weeks after surgery.

### Study period

After the experimental stage, the animals were kept in cages according to the group. After anesthetic recovery, they received liquid diet at first, followed by a balanced diet and water *ad libitum*, and were placed in isolation.

Five animals were sacrificed two weeks after surgery, and the other five twelve weeks after surgery. No animals were lost during the study period.

### Histological processing

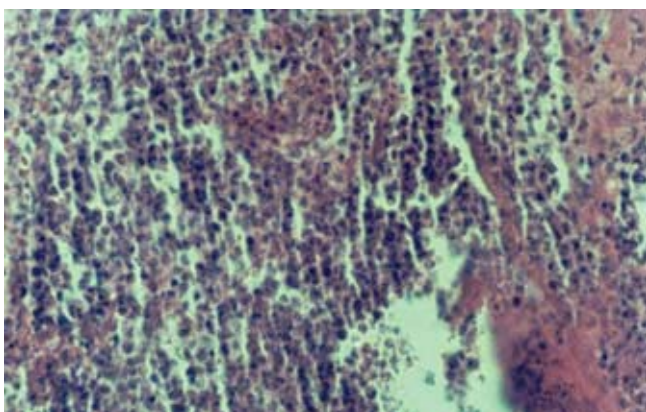
Block sections were obtained from the surgical areas, stored in 10% formalin for 72 hours and submitted to histological preparation and light microscopy evaluation. Histological preparation comprised dehydration in alcohol in an automatic processor including 70%, 80%, 90% and absolute alcohol, followed by diaphanization with two immersions in xylol and impregnation with paraffin. Four-micrometer-thick sections were obtained by means of a microtome, comprising the surgical areas where both types of cement were inserted. The sections were stained with hematoxylin and eosin.

The entire histological processing was performed at the Morphology and Embryology Laboratory of the Bahia State School of Medicine and Public Health. Analysis of the sections was conducted by means of a double-blind study. The technician recorded the sections and the pathologist carried out the readings. Microscopic analysis comprised observation of the most remarkable histological phenomena occurring at the surgical areas.

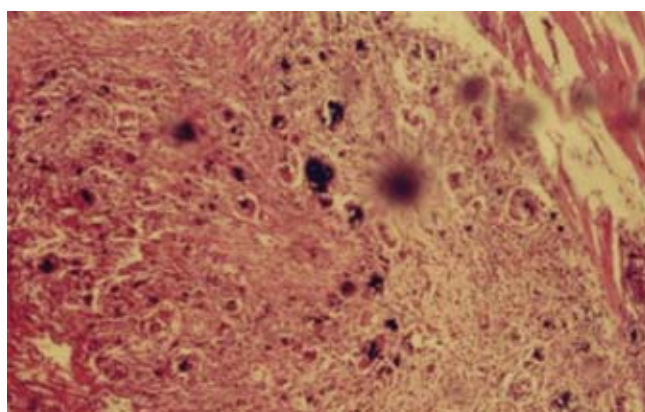
The data achieved were submitted to statistical analysis by means of the Sigmastat (Jeandel Scientific) and SPSS 7.5 softwares, with application of the Student's t test and Mann-Whitney test for paired analyses. The Mann-Whitney test was employed whenever the data did not demonstrate normality or the corresponding variance.

## Results

The following findings were observed for Group I (sacrifice two weeks after surgery) for the Portland cement: mild to moderate inflammatory infiltrate in specific areas, fibrous tissue, congested vessels, capillary neoformation, fibroblasts, neutrophils and macrophages. Fibrin was present in two of five specimens. One specimen did not exhibit fibrous tissue, macrophages and fibroblasts. Plasma cells, lymphocytes, eosinophils and giant cells were not observed in any specimen in Group I. The specimens in Group I for the Portland cement suggested an acute inflammatory process (figure 1).



**Figure 1** - Portland cement - Group 1. Intense inflammatory infiltrate. HE, 40X

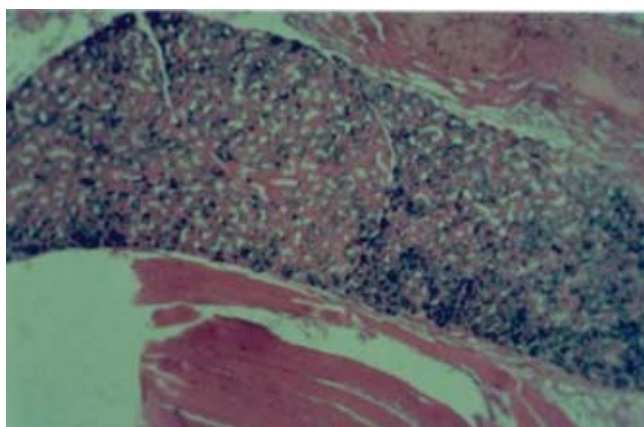


**Figure 2** - Portland cement - Group 2. Chronic inflammatory process. HE, 10X

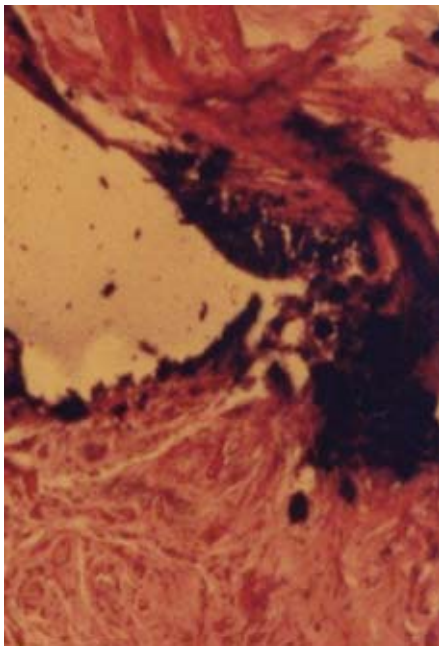
Concerning Group II (sacrifice twelve weeks after surgery) for the Portland cement, there was resolution of the inflammatory process, granulomatous reaction, formation of fibrous tissue, increased vascularization, and chronic inflammatory reaction with predominance of lymphocytes, macrophages and fibroblasts. One specimen demonstrated normal connective tissue with scarce macrophages. Neutrophils, eosinophils and plasma cells were not found on this group, as well as necrosis and non-congested vessels.

The findings in Group II suggested that the acute inflammation observed in Group I was progressing to chronic inflammation (figure 2).

Group I for the MTA displayed absence of acute inflammatory cells, inflammatory infiltrate with presence of macrophages, fibroblasts, fibrous tissue, congested vessels, increased vascularization and neoformed capillaries. The inflammatory reaction in this group was mild (figure 3).



**Figure 3** - MTA - Group 1. Cement granules and absence of inflammatory cells, formation of fibrous tissue. HE, 10X



**Figure 4** - MTA - Group 2. Cement granules and fibrous tissue. HE, 40X

The findings for Group II for the MTA included vascular proliferation, resolution of the inflammatory process, normal connective tissue, fibrous tissue, fibroblasts and macrophages (figure 4).

Non-congested vessels, necrosis, eosinophils, lymphocytes, plasma cells and giant cells were not observed in both Groups I and II. The tissue appearance was normal in Group II. Statistical analysis comprised combination of the non-cellular components for the MTA (table I).

**Table I** - Combination of the non-cellular components

Non-cellular components	Combination Mineral Trioxide Aggregate X Portland cement	
	Group 1	Group 2
	Fibrous tissue	P=0.690**
Congested vessels	P=1.000*	P=0.310**

for p values <0.05

\* Student's t test

\*\* Mann-Whitney test

None of the items evaluated on this table demonstrated a statistically significant difference, since all p values were higher than 0.05. Non-congested vessels and necrosis were not observed on this table, since they were not observed in any sample on the dichotomous analysis. Table II demonstrates the combination of the cellular

components between the MTA and the Portland cement for Groups I and II.

**Table II** - P value for the combination of MTA and Portland cement - cellular components

Cellular components	Combination Mineral Trioxide Aggregate X Portland cement	
	Group 1	Group 2
	Fibroblasts	P=0.690**
Macrophages	P=0.690**	-
Neutrophils	P<0.0001*	-
Lymphocytes	-	P=0.151**
Giant cells	-	P=0.032**

for p values < 0.05

\* Student's t test

\*\* Mann-Whitney test

There was a statistically significant difference ( $p < 0.0001$ ) concerning the neutrophils in Group I, as well as for the giant cells in Group II ( $p = 0.032$ ). Eosinophils and plasma cells were not observed for the MTA or Portland cement on both groups.

Combination of the non-cellular and cellular components conducted between Groups I and II for the same material (table III) only allowed evaluation of the following items: fibrous tissue (non-cellular components), being  $p = 0.690$  for the MTA (Mann-Whitney test) and  $p = 1.000$  for the Portland cement (Student's t test), both for p values <0.05, thus with no statistically significant difference. Evaluation of the cellular components comprised fibroblasts and macrophages. There was no statistically significant difference for the fibroblasts, since  $p = 1.000$  was found for the MTA (Student's t test) and  $p = 0.690$  for the Portland cement (Mann-Whitney test), for  $p < 0.05$ .

**Table III** - P value for the combination of Groups 1 and 2 (cellular and non-cellular components) for the cements evaluated

Components	Combination Mineral Trioxide Aggregate X Portland cement	
	Group 1 X Group 2	Group 1 X Group 2
	Fibrous tissue (non-cellular)	P=0.690**
Fibroblasts (cellular)	P=1.000*	P=0.690**
Macrophages (cellular)	P=1.000*	P=0.690**

for p values < 0.05

\* Student's t test

\*\* Mann-Whitney test

## Discussion

Before a dental material is employed on human beings, it must be submitted to several studies in order to demonstrate that it may be applied in a safe and efficient manner. This study was conducted in rodents because this experimental model met the basic criteria required for such study, in addition to the easy access and control of the diet and general health of the animals. The veterinary and biologist in charge of the animal laboratory of University of Feira de Santana supervised all procedures, since pre-anesthetics and anesthetics up to the care required during the post-operative period, such as feeding of the animals.

The mean weight of the selected rats was 313.73g and they were characterized as young adults. After surgery, the entire sample received controlled diet and water *ad libitum*. This homogeneous sample allowed reliable results.

The MTA is a new material in Dentistry and as such it still must be submitted to several studies. Investigations on the Portland cement have recently been initiated in Dentistry, since it was observed that this cement basically had the same chemical composition as the Mineral Trioxide Aggregate, besides the addition of bismuth to provide radiopacity [2, 9]. For that reason, comparative studies between both cements have been conducted by some investigators. The present study aimed at observing whether both cements presented similar histological aspects.

Both materials employed in this study were prepared with saline solution, because it is a sterile substance and therefore would not influence the outcomes. Manipulation was performed until paste consistency was reached, as mentioned in the studies of Lee *et al.* (1993) and Torabinejad *et al.* (1999).

One study conducted by Torabinejad *et al.* (1995) [8] demonstrated that calcium and phosphate are the main ions present in the Mineral Trioxide Aggregate. Since these components are also the main components of the dental hard tissues, this may contribute to its biological compatibility with the surrounding tissues. These findings highlight the biocompatibility of MTA, which was also observed on the present study.

Holland *et al.* (2001) [3] conducted an investigation on the reaction of the subcutaneous tissue of rats to the implantation of dentin tubes filled with Portland cement, Mineral Trioxide Aggregate or calcium hydroxide. All materials analyzed demonstrated similar outcomes. The authors concluded that the mechanism of action of these materials may be similar to each other. The calcium hydroxide is widely employed in Dentistry and has

been more investigated than the Portland cement (in Dentistry) and the Mineral Trioxide Aggregate, which is much more recent. It is known that both calcium hydroxide and the Mineral Trioxide Aggregate display properties such as biocompatibility, stimulation of the formation of hard tissue and antimicrobial action, which make them the material of choice for several clinical procedures. On the other hand, the Portland cement should be further investigated before any conclusions may be drawn about its possible properties for clinical application. The results observed by the authors are corroborated by the present study. The first group demonstrated a very large difference between the Mineral Trioxide Aggregate and the Portland cement, having the MTA exhibited a milder inflammation whereas the Portland cement revealed a more acute inflammation. As regards Group II, the results observed were similar, with normal areas of connective tissue for the MTA and a tendency towards chronification for the Portland cement, representing resolution of the inflammatory process.

Soares (1996) [7] histologically evaluated the pulp response to the Mineral Trioxide Aggregate compared to the calcium hydroxide in dog teeth submitted to pulpotomy. The author suggests that the repair mechanism of MTA must be similar to that of the calcium hydroxide, due to the similar histological aspects. Because of such similarity in the histological aspects between MTA and calcium hydroxide, and between the MTA and the Portland cement in Group II of the present study, it may be suggested that the Portland cement may also present similar properties to the calcium hydroxide.

In the present study, fibroblasts and fibrous tissue, as well as macrophages, were observed in almost all specimens of both groups for both Mineral Trioxide Aggregate and Portland cement.

Giant cells were just observed in Group II for the Portland cement, representing an attempt of resolution of the inflammatory process. Lymphocytes were also found in some specimens of Group II for the Portland cement.

It should be noticed that both cements displayed a tendency towards chronification in Group II, therefore indicating biocompatibility. These finding is in agreement with Holland *et al.* (2001) [3].

Congested vessels were observed in both groups for the Portland cement in the present study, revealing the inflammatory status of the specimens, however for the MTA they were found just in Group I. Neutrophils were also observed in Group I for the Portland cement, characterizing the inflammation in this group as acute.

A mild inflammatory infiltrate was found for Group I for the MTA, with no acute inflammatory cells.

From all analyses conducted, statistically significant difference was just found for the neutrophils in Group I (combination between MTA and the Portland cement) and for the giant cells in Group II.

A remarkable finding was the more intense inflammation for the Portland cement when compared to the Mineral Trioxide Aggregate at the first study period, followed by similar reactions at the second study period.

## Conclusion

Considering the present results, the following could be concluded as to the histological evaluation of the MTA and Portland cement:

1. The inflammatory reaction to both cements after two weeks of insertion is acute, being the MTA considerably gentler than the Portland cement;
2. At the 12-week period, there was a tendency towards a histological similarity between both cements concerning the tissue components.

## References

1. Busato ALS, Vieira MVB, González PAH, Miguens Jr SAQ, Costa SP, Rossi TR. Agregado de trióxido mineral – indicações clínicas de um novo cimento dentário. *JBC*. 1999;3(18):32-4.
2. Estrela C, Bammann LL, Estrela CRA, Silva RS, Pécora JD. Antimicrobial and chemical study of MTA, portland cement, calcium hydroxide paste, sealapex and dycal. *Braz Dent J*. 2000;11:3-9.
3. Holland R, Souza V, Nery MJ, Faraco Jr IM., Bernabé PF, Otaboni Filho JA et al. Reaction of rat connective tissue to implanted dentin tubes filled with mineral trioxide aggregate, Portland cement or calcium hydroxide. *Braz Dent J*. 2001;12:3-8.
4. Lee SJ, Monsef M, Torabinejad M. The sealing ability of a mineral trioxide aggregate for repair of lateral root perforations. *J Endod*. 1993;19:541-4.
5. Leonardo MR, Leal JM. *Endodontia: tratamento de canais radiculares*. 3. ed. São Paulo: Panamericana; 1998. p.737-99.
6. Pitt Ford TR, Torabinejad M, Abedi HR, Bakland LK, Kariyawasam SP. Mineral trioxide aggregate as a pulp capping material. *JADA*. 1996;127:1491-4.
7. Soares IML. Resposta pulpar ao MTA – agregado de trióxido mineral – comparada ao hidróxido de cálcio, em pulpotomias. *Histológico em dentes de cães*. [Tese Professor Titular]. Florianópolis: Universidade Federal de Santa Catarina, Faculdade de Odontologia; 1996.
8. Torabinejad M, Wilder Smith P, Pitt Ford TR. Comparative investigation of marginal adaptation of mineral trioxide aggregate and ather commonly used root end filling materials. *J Endod*. 1995 June;21(6):295-9.
9. Torabinejad M, Hong CU, McDonald F, Pitt Ford TR. Physical and chemical properties of a new root-end filling material. *J Endod*. 1995 July;21(7):349-53.
10. Torabinejad M, Hong CU, Pitt Ford TR. Tissue reaction to implanted Super-EBA and mineral trioxide aggregate in the mandibles of guinea pigs: a preliminary report. *J Endod*. 1995;21(9):569-71.
11. Torabinejad M, Chivian N. Clinical applications of MTA. *J Endod*. 1999;25:197-205.