

Case Report Article

Consequences of dental trauma to the primary teeth on the permanent dentition

Carla Miranda¹
Betsy Killian Martins Luiz²
Mabel Mariela Rodriguez Cordeiro³

Corresponding author:

Carla Miranda
Rua João Pio Duarte e Silva, n. 94, apto. 201 – Córrego Grande
CEP 88.037-000 – Florianópolis – SC – Brasil
E-mail: ca_mirand@yahoo.com.br

¹ Department of Dentistry, University of Southern Santa Catarina – Tubarão – SC – Brazil.

² Department of Dentistry, Federal University of Santa Catarina – Florianópolis – SC – Brazil.

³ Department of Morphological Sciences, Federal University of Santa Catarina – Florianópolis – SC – Brazil.

Received for publication: October 18, 2011. Accepted for publication: March 8, 2012.

Keywords: injuries
tooth; deciduous;
dentition permanent.

Abstract

Introduction: Dental trauma to primary teeth or to the jaws may cause disorders on the development of permanent successor teeth. The alterations may either occur at the time of accident or be caused by post-traumatic consequences. **Objective:** The aim of this paper is to present cases of alterations on permanent dentition following dental trauma to primary teeth. **Case reports:** Three cases are presented in this paper. The severity of the post-traumatic sequels shown by the permanent teeth kept a direct relationship with the extent of the impact and patient's age at the accident. These sequels resulted in whitish or brownish opacities, enamel hypoplasia, root dilacerations, and total arrest of root development. **Conclusion:** It can be concluded that the protocols for patients who had experienced dental trauma must observe a systematic clinical and radiographic follow-up as well as alternatives of treatment for the primary and permanent teeth involved. Prognostics and treatments related to the sequels in permanent teeth may be obtained from a close analysis of clinical and radiographic aspects, avoiding more damages to the stomatognathic system. The severity of the sequels is directly related to the degree of permanent tooth formation (child's age), type of dental trauma and extent of the impact.

Introduction

Primary teeth and their permanent successors must be understood as interdependent units, where each one of them interacts with and depends upon the other. This relationship can be altered by mechanical traumas or as a consequence of tooth decay lesions. The loss of homeostasis from this unit impacts on the tooth and the surrounding tissues, to different degrees of intensity [3].

Dental trauma to primary teeth and/or to the jaws may disturb the development of permanent teeth in 12 to 69% of cases [1]. These alterations may occur at the time of accident as consequences of the impact strength itself over the bone tissue or permanent tooth germ or even as consequences of mechanical impact of the primary tooth apex over its permanent successor. Alterations caused at medium- and long-terms from post-traumatic sequels should also be taken into consideration [7].

There is a direct relationship between the severity of morphologic and mineralization alterations, which may affect the permanent germ, with the type of dental trauma to a primary tooth and degree of development of the permanent successor germ. Intrusive luxation and avulsion are responsible for the largest disturbances in permanent tooth development, followed by extrusive luxation and lateral luxation. When a dental trauma happens at an age ranging from 0 to 4 years old, the percentage of permanent teeth affected regarding to morphologic and/or mineralization aspects may be higher than 50% [1]. The frequency of those disturbances diminishes with aging. Jaw fractures and surgical procedures performed as treatment may also affect the development of permanent teeth [1].

Literature shows a range of alterations that may involve the permanent successor tooth, from minimal enamel opacities, hypoplasia and hypocalcification, with whitish or brownish defects, crown dilacerations, malformation resembling an odontoma, duplication, angulations and dilacerations of the root, arrest of root development, germ sequestration, ectopic eruption, to non-irruption of the permanent tooth [2, 3, 7, 9, 10, 12, 16-20].

Immediately after a dental alveolar trauma in the primary dentition, no definite statement can be made regarding the possible secondary damage despite clinical and radiological examinations. However, the severity of the alteration involving the development of the permanent successor germ may be foreseen as the type of traumatic primary tooth injury combined to the age of the child at the time of the accident can indicate the probability of subsequent secondary damages [15]. Accordingly to

Nolla [13], mineralization stage of the germ can be checked on radiographs; however, the damages are unforeseeable. It is of note, however, that when the dental trauma or its sequels to the primary tooth are coincident with the precocious stages of permanent germ development, the resulted damage will be more severe, as this alteration will occur on the follicle tissues [8, 18]. During cap, bell or matrix deposition stages, the alterations will be more severe affecting the morphology of the tooth. If the dental trauma happens during matrix mineralization or maturation stages the damages will be on the tissue microstructure, showing enamel opacities, but the tooth morphology will be intact. There is more interference during odontogenesis when the tooth is at Nolla's 2 and 3 stages, i.e. at the very beginning of crown mineralization. Ankylosis of the tooth to the top of the bone crypt, arresting the eruption movements, and then retaining the tooth may occur when there is destruction of the reduced enamel epithelium [1]. Cervical sheath is responsible for the progression of dental development through root formation. The root starts to develop when the inner and outer epithelia of the enamel organ fuse below the level of crown cervical enamel to produce a bilayered epithelial sheath termed Hertwig's epithelial root sheath (HERS), after the crown is completely formed. Although this HERS is highly resistant to trauma it may be affected by a deep intrusion of the primary tooth, showing alterations in the root axis or even complete arrest of the root development. Therefore, depending on the intensity of the trauma and the moment of tooth development in which it happens, a partial or total arrestment of root development may occur, at different stages of root formation [1].

In a general way, the real extension of the damages on a permanent germ will be known only after this tooth erupts into the oral cavity, or even does not erupt, showing radiographically detected eruption problems [7].

This report describes cases of permanent teeth showing alterations in the eruption pattern and/or development, as consequences of dental trauma to their primary tooth predecessors. Probably, the affected tissues were the dental follicle, the cervical sheath, the enamel organ and its ameloblasts, the reduced enamel epithelium and HERS.

Case reports

According to the clinical and radiological characteristics of each case, a follow-up program

was scheduled, at predetermined intervals, with monitoring of the development of each case, and, additional treatments or therapies were performed (aesthetic restorations, space recuperations, orthodontics, and prosthodontics).

Case 1

A twelve-year-old girl attended the Pediatric Dentistry Clinic showing tooth #11 lightly rotated, and tooth #21 presenting alteration in the crown morphology involving enamel and dentin (figure 1A, B). Teeth #22 and #23 were clinically and radiographically absent (figure 1A, B, C). During anamnesis, the patient and her tutor reported they had looked for prior treatment to improve

aesthetics. At that time, teeth #22 and #23 were extracted by the dentist because “they had no conditions of being kept in place as their crown and root were damaged”. After that, patient was referred to the university to have the root canal of tooth #21 treated. Anamnesis also revealed that when the patient was 5½ years old she hit her left upper jaw against a sidewalk curb. She was brought to a hospital where she was submitted to a local surgery to have a maxillary fracture reduced. At that time, the primary teeth #51, #61, #62, and #63 were extracted. At the Pediatric Dentistry Clinic a provisory prosthetic crown was done and she was referred to Orthodontics and Prosthodontics treatment (figure 1D).

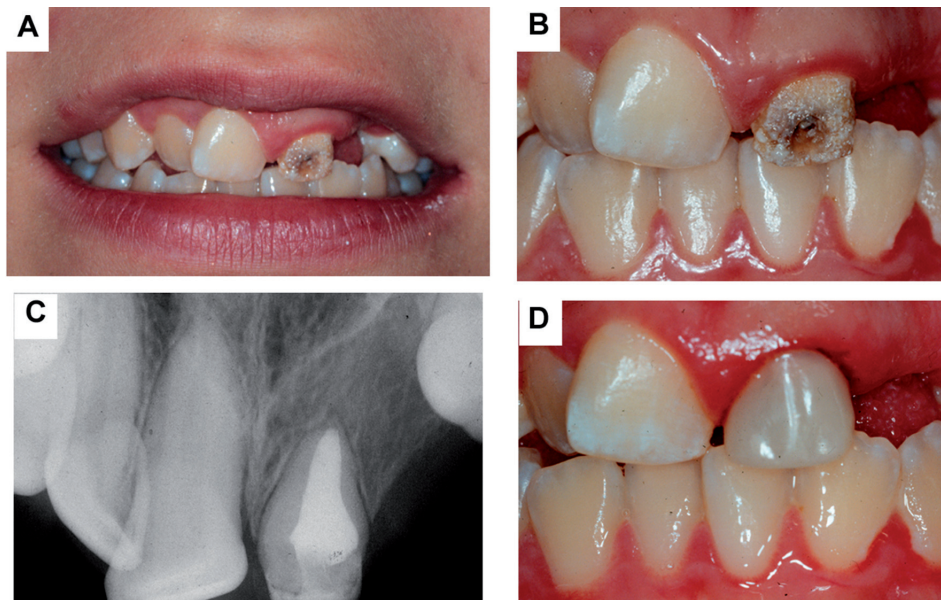


Figure 1 - Case showing alterations in the eruption pattern in tooth #11 (A), in the development of dental tissues (enamel and dentin) in teeth #11 and #21 (B), and absence of tooth #22 and #23 (C). D shows a provisional prosthetics crown made to protect the tooth #21

Case 2

A 13-year-old boy attended Pediatric Dentistry Clinic showing total disharmony of occlusion, aesthetics, and morphology in teeth #12, #11 and #22 (figure 2 A-D). He also showed gingivitis at upper and lower incisors' region and midline deviation. Lateral incisors were partially erupted and showed whitish and yellowish enamel defects. Right upper central incisor showed, together with the already cited alterations, brownish enamel marks. At the gingival area corresponding to the apical region of the left lateral upper incisor, there was a protuberance which made this local whitish

and hard at touch corresponding to a “tattoo” in outstanding feature of the root apex of tooth #22. Radiographically, the crowns presented radiolucent areas clinically corresponding to the enamel defects (dips) (figure 2E). Root aspect was considered normal for teeth #12 and #11, questionable for tooth #22 and total arrest of root development to tooth #21. Anamnesis revealed that the patient suffered a backward kick from a horse when he was almost 3 years old. Patient attended only to 3 appointments, when it was performed therapeutic measures related to oral hygiene education, in order to reduce local inflammation, and then he did not show up anymore.

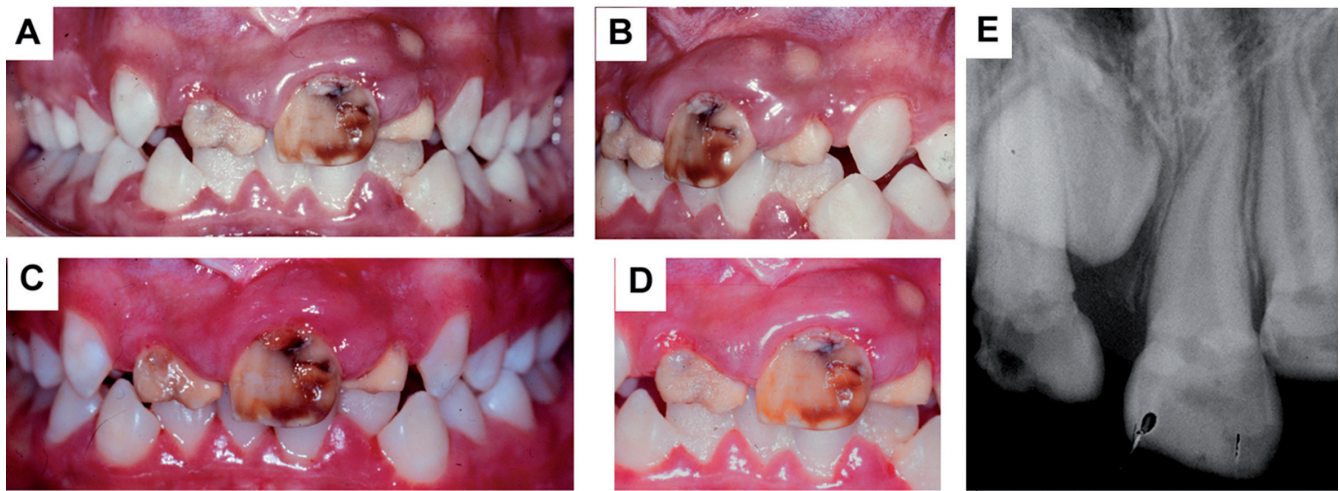


Figure 2 - Case showing alterations in the development of teeth #12, #11 and #22. Complete disharmony of occlusion and aesthetics, associated to gingivitis (A-C). Presence of a gingival protuberance corresponding to the root apex of the tooth #22 (D). Tooth #21 is non-erupted (E)

Case 3

An 8-year-old girl attended Pediatric Dentistry Clinic complaining about a pain related to the left upper central incisor during ingestion of foods and drinks, mainly cold ones. Her second complaint was regarding the lack of aesthetic that the tooth presented (figure 3A, B). During anamnesis her mother reported that she suffered a dental trauma on her primary predecessor when she was 4 years old in which the tooth “came completely into the

gingiva”. That primary tooth was extracted days after the trauma episode. Clinically, the permanent tooth showed a yellowish-brownish color, with depressions in the enamel surface and in dentin, with a large area of dentin exposed directly to the oral environment. The enamel defect was protected with glass ionomer cement and it was performed a tooth cleaning procedure and fluoride application before referring the patient to the Operative Dentistry Clinic in order to restore completely the aesthetic of the tooth (figure 3C, D).

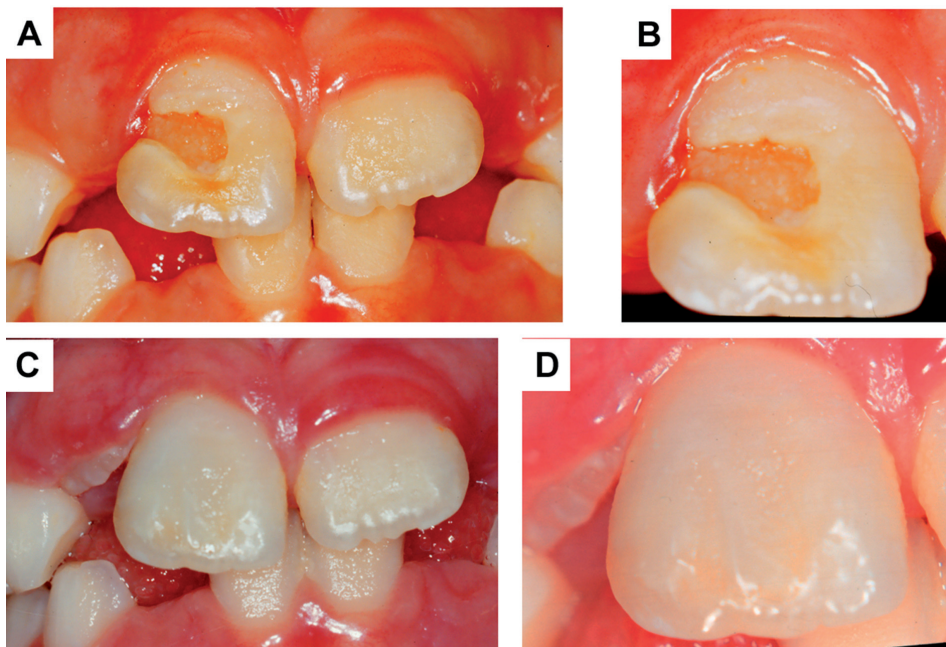


Figure 3 - Tooth #21 showing enamel hypoplasia, exposing underneath dentin, which stimulated pain (A-B). C and D show the same tooth after aesthetic restoration

Discussion

Although there is a high incidence of primary teeth affected with dental trauma and/or periradicular inflammation/infection, few permanent successor teeth show structural alterations, generally with problems in the pattern of eruption as the most common consequence. Matsumiya [11] stated that this may be related to factors such as the presence of a defense phenomenon in the permanent tooth germ follicle, usually more efficient at preventing the entrance of infection in the permanent enamel organ. Another factor would be the vital force of the reduced enamel epithelium, once after regression of inflammation, the viable ameloblasts will return to their functions.

Yet, there is a quick formation of gum fistulae, restricting the inflammation to the proximities of the permanent tooth germ. In this situation, the germ is rarely affected by the periradicular inflammation even in a relatively serious case. Even if these factors are accepted as true, we cannot admit that they are sufficient to protect the permanent tooth germ from the chemical mediators of inflammation, or from the products of bacterial metabolism, or even from the proteolysis of a necrotic pulp tissue, especially when these are found at very early development stages [1].

Our observations agree with Weinlander [19], who stated that when injury occurs precociously, at the initial Nolla's stages, even the removal of the primary tooth may not correct the damage to the permanent tooth (cases 2 and 3), but the extent of aggression can be confined whether normal periradicular conditions are restored.

Enamel defects observed in our cases sustain Coll and Sadrian's [4] statement, that these defects are related either to the presence of a mechanical trauma or to the presence of inflammation or periradicular infection in the predecessor primary tooth, before endodontic or extraction treatment (cases 2 and 3). These alterations would not be a consequence of root canal therapy or tooth extraction, even in those cases where there is a large root resorption in the primary tooth.

It is important to monitor the evolution of a case of dental trauma on a primary tooth as pathologic root resorptions are very prevalent after trauma episodes and need correct diagnosis and treatment [14]. Furthermore, it is necessary to evaluate the need of root canal treatment or even tooth extraction in order to avoid that inflammation or infection might affect the development of the permanent successor tooth germ [3]. Even after the primary tooth is no longer present at the oral cavity, the eruption of the permanent tooth should be followed-up to verify possible damages to this tooth and to perform treatment as soon as its need is diagnosed [3].

Endodontic or extraction treatment does not correct alterations that have already been caused in the permanent tooth germ, but avoid it worsening [2, 3, 7]. Extraction does not stop the premature eruption of the permanent tooth, and even increases the risk of space loss in the dental arch, which is an additional concern regarding space maintenance or recuperation and in the follow up of this treatment. A successful endodontic treatment avoids premature eruption, as it restores tissue balance, allowing the primary tooth to complete its biological cycle and perform all of its main functions (i.e. mastication, space maintenance, eruption guide, etc.) [3].

Premature loss of a primary tooth can unleash eruption problems in the permanent successor tooth, even if treatments are done to recover and maintain space, as there is no way to accelerate the root formation or stop the eruption of a permanent tooth with immature root development. This agrees with Fanning's [9] report that the degree of permanent tooth development does not alter after the extraction of the primary predecessor, and that an eruption impulse occurs after the extraction of the primary element, regardless of the development stage of the permanent germ or the age of the child.

Alterations involving the dental crown are aesthetic and usually do not involve immediate cosmetic intervention, especially in very young patients [6]. When this need exists, they can be conducted after the eruption of the tooth through restorative processes or prosthesis (case 3). However, alterations that involve root structures not only compromise the permanence of the tooth in the arch, but also can unleash both aesthetical and functional problems [3].

The cervical sheath for root development forms only after complete crown formation. This happens when the inner and outer epithelia fuse becoming the Hertwig's epithelial root sheath (HERS) [12]. Dental trauma in a primary tooth may compromise root development if it happens when the crown of the successor tooth is not completely formed and fusion of both epithelia and the emergence of HERS may be impeded.

A primary tooth loses its importance when its presence is deleterious to its permanent successor germ. However, when the treatment of choice is the extraction of the primary tooth, all the efforts must be headed for the successor tooth, to restore patient's emotional state, through the reestablishment of his stomatognathic system and, mainly, the regaining of a healthy smile (case 1).

The maintenance or the rescue of a healthy condition of primary and permanent teeth is vital to the local balance of oral structures and no less important to the general health of the young patient.

Conclusion

It can be concluded that the protocols for patients who had experienced dental trauma must observe a systematic clinical and radiographic follow-up as well as alternatives of treatment for the primary and permanent teeth involved. Prognosis and treatments related to the sequels in permanent teeth may be obtained from a close analysis of clinical and radiographic aspects, avoiding more damages to the stomatognathic system. The severity of the sequels is directly related to the degree of permanent tooth formation (child's age), type of dental trauma and extent of the impact.

Acknowledgements

Authors thank Dr. Maria José de Carvalho Rocha for her invaluable contribution to this article.

References

1. Andreasen JO, Andreasen FM, Andersson L. Textbook and color atlas of traumatic injuries to the teeth. New Jersey: Wiley-Blackwell; 2007.
2. Brook AH, Winter GB, Osborne JA. The occurrence of benign cystic lesions of the jaws in children. *Proc Br Paedod Soc.* 1971;1:16-9.
3. Cordeiro MMR, Rocha MJC. The effects of periradicular inflammation and infection on a primary tooth and permanent developing successor. *J Clin Pediatr Dent.* 2005;29:193-200.
4. Coll JA, Sadrian R. Predicting pulpectomy success and its relationship to exfoliation and its succedaneous dentition. *Pediatr Dent.* 1996;18:57-63.
5. Da Silva ALR, Ferelle A, Iwakura ML, Cunha RF. Effects on permanent teeth after luxation injuries to the primary predecessors: a study in children assisted at an emergency service. *Dent Traumatol.* 2009;25:165-70.
6. Daly D, Waldron JM. Molar incisor hypomineralisation: clinical management of the young patient. *J Ir Dent Assoc.* 2009;55:83-6.
7. De Amorim LFG, Estrela C, da Costa LR. Effects of traumatic dental injuries to primary teeth on permanent teeth – a clinical follow-up study. *Dent Traumatol.* 2010;28:1-5.
8. Do Espírito Santo Jácomo DR, Campos V. Prevalence of sequelae in the permanent anterior teeth after trauma in their predecessors: a longitudinal study of 8 years. *Dent Traumatol.* 2009;25:300-4.
9. Fanning EA. Effect of extraction of deciduous molars on the formation and eruption of their successors. *Angle Orthodont.* 1962;32:44-53.
10. Güngör HC, Püşman E, Uysal S. Eruption delay and sequelae in permanent incisors following intrusive luxation in primary dentition: a case report. *Dent Traumatol.* 2011;27:156-8.
11. Matsumiya S. Experimental pathological study on the effect of treatment of infected root canals in the deciduous tooth on growth of permanent tooth germ. *Int Dent J.* 1968;18:546-59.
12. Nanci A. Ten Cate's oral histology. Missouri: Mosby; 2008.
13. Nolla CM. The development of the permanent teeth. *ASDC J Dent Child.* 1960;27:254-66.
14. Santos BOA, Mendonça DS, Sousa DL, Moreira Neto JJS, Araújo RBR. Root resorption after dental traumas: classification and clinical, radiographic and histologic aspects. *RSBO.* 2011;8:439-45.
15. Sennhenn-Kirchner S, Jacobs HG. Traumatic injuries to the primary dentition and effects on the permanent successors – a clinical follow-up study. *Dental Traumatology.* 2006;22:237-41.
16. Tewari N, Pandey RK. Multiple abnormalities in permanent maxillary incisors following trauma to the primary dentition. *J Indian Soc Pedod Prev Dent.* 2011;29:161-4.
17. Valderhaug J. Periapical inflammation in primary teeth and its effect on the permanent successors. *Int J Oral Surg.* 1974;3:171-82.
18. Von Arx T. Developmental disturbances of permanent teeth following trauma to the primary dentition. *Aust Dent J.* 1993;38:1-10.
19. Weinlander GH. Clinical effect of formaldehyde preparations in pulpotomy for primary molars. *J Can Dent Assoc.* 1971;37:154-8.
20. Zilberman Y, Fuks A, Ben Bassat Y, Brin I, Lustmann J. Effect of trauma to primary incisors on root development of their permanent successors. *Pediatr Dent.* 1986;8:289-93.