

Case Report Article

Contribution of cone beam computed tomography to suggest a hypothesis of odontogenic keratocyst in the diagnosis of a bone lesion: a case report

Anna Karla da Silva Lourenço¹
Luciano Sandoval Carneiro^{1,2}
Júlio Cesar Pedro³

Corresponding author:

Luciano Sandoval Carneiro
Universidade Paulista

Instituto de Ciências da Saúde, Departamento de Odontologia, Divisão de Radiologia Odontológica
SGAS Quadra 913, s/n – Conjunto B – Asa Sul
CEP 70390-130 – Brasília – DF – Brasil
E-mail: lucsanc@yahoo.com.br

¹ Institute of Health Sciences, Department of Dentistry, Dental Radiology Division, Universidade Paulista – Brasília – DF – Brazil.

² State Department of Health of the Federal District, Department of Dentistry, Dental Radiology Division – Brasília – DF – Brazil.

³ Private clinic São Lucas Radiologia Odontológica – São Carlos – SP – Brazil.

Received for publication: November 12, 2021. Accepted for publication: August 1, 2022.

Keywords:

cone beam computed tomography;
odontogenic cyst;
diagnosis.

Abstract

Introduction: In the literature, several studies have investigated cone beam computed tomography (CBCT) findings of microscopically confirmed odontogenic keratocysts (OK). Such data can be useful on clinical routine in the diagnosis of bone lesions to define a hypothesis of OK before surgical resection. **Objective:** To report a clinical case of an extensive bone lesion in the mandible, which tomographic and clinical findings suggested OK as the first hypothesis. **Case report:** A 14-year-old male underwent a CBCT scan of the mandible for investigating an asymptomatic radiolucent bone lesion detected in a panoramic radiography. Clinically no swelling was evident and the adjacent teeth presented positive response to pulpal sensitivity test. CBCT images revealed a hypodense and unilocular lesion extending from mandibular left central incisor region to mandibular left first molar site; from jaw base to periapical region of the adjacent teeth; from buccal to lingual bone cortical. At the site of the lesion, there was erosion of the buccal and lingual bone cortical, which presented a mild expansion. Additionally, sectional images showed scalloped edges of the lesion, slight external root resorption at the apex of mandibular left second premolar, subtle incomplete septa and mandibular canal

involvement by the lesion. **Conclusion:** The relevant CBCT findings contributed to suggest a probable hypothesis of OK in the diagnosis of a mandibular bone lesion. However, final diagnosis depends on microscopic examination.

Introduction

The OK is an intraosseous lesion derived from remnants of the dental lamina, located in the alveolar bone [3, 10]. This pathological entity was included as an odontogenic cyst in the classification of odontogenic bony lesions published in 1992 by World Health Organization (WHO). However, on the third edition of such classification, published in 2005, the lesion was included as a benign odontogenic tumor, due to its aggressive biologic behavior, recurrence high incidence, association to nevoid basal cell carcinoma syndrome and mutation on tumor suppressor gene PTCH (Protein patched homolog). Although, in 2017 on the fourth edition the same classification, the lesion came back to the odontogenic cysts group because evidences were insufficient to consider it as a neoplasm [1, 4, 6, 10, 11, 20].

The lesion corresponds to around 10% of the jaw cysts [15], with a higher growth potential than the others. Researches indicate greater predilection for men, aged between second and third decades of life [13].

The OK usually appears at the body and ramus of the mandible, for around 2/3 of the cases. The pathologic entity grows slowly, usually asymptomatic [1, 4, 6]. Recurrence rate is high, between 25 and 60% [17]. The detection of many OK at the jaws usually is associated to nevoid basal cell carcinoma syndrome or Gorlin Goltz syndrome [5, 14, 22], which recurrence rate can reach 82% [7].

Radiographically, the OK usually presents as a radiolucent, unilocular and well-defined lesion with radiopaque margins [4]. For around 30% of cases are multilocular type. The radiographic images can also reveal root resorption, dental displacement or retained tooth associated to the lesion [9]. Frequently the detection of OK occurs on routine radiographic examinations because usually there is not symptomatology or bone cortical expansion associated to the lesion [4, 6].

Considering that CBCT is an advanced imaging technique, there are many studies in the literature investigating peculiarities on CBCT images, which contribute to direct the differential diagnosis of a bone lesion to OK. Thus, the aim of this study was to report the case of a patient with an extensive bone lesion in the mandible, which CBCT findings suggested a probable OK.

Case report

A 14-year-old male went to a private dental radiology clinic in São Carlos – SP. He presented a form requesting a CBCT scan of the mandible for investigating a bone lesion detected in a panoramic radiography. The following information were in the form: “An asymptomatic radiolucent bone lesion was detected in the left side of the mandible; the intra and extraoral clinic evaluation revealed no phlogistic signs or swelling; the lining mucosa presented with normal appearance; the adjacent teeth presented positive response to pulpal sensitivity test; the patient has a regular oral hygiene.”

The patient underwent a CBCT scan (i-CAT®, Imaging Sciences International, Hatfield, USA) with the following parameters: 0.25 mm voxel size, 120 kVp and 5 mA. Subsequently, multiplanar reconstructions and the cross-sectional images were analyzed using a specific software (Xoran CAT™, Xoran Technologies, Ann Arbor, MI).

CBCT images revealed a hypodense and unilocular lesion extending from mandibular left central incisor region to mandibular left first molar site; from jaw base to periapical region of the adjacent teeth (figure 1); from buccal to lingual bone cortical (figures 2A and 2B). At the site of the lesion, there was erosion of the buccal and lingual bone corticals. However, although the lesion was extensive, there was a mild expansion of such corticals (figures 2A and 2B).

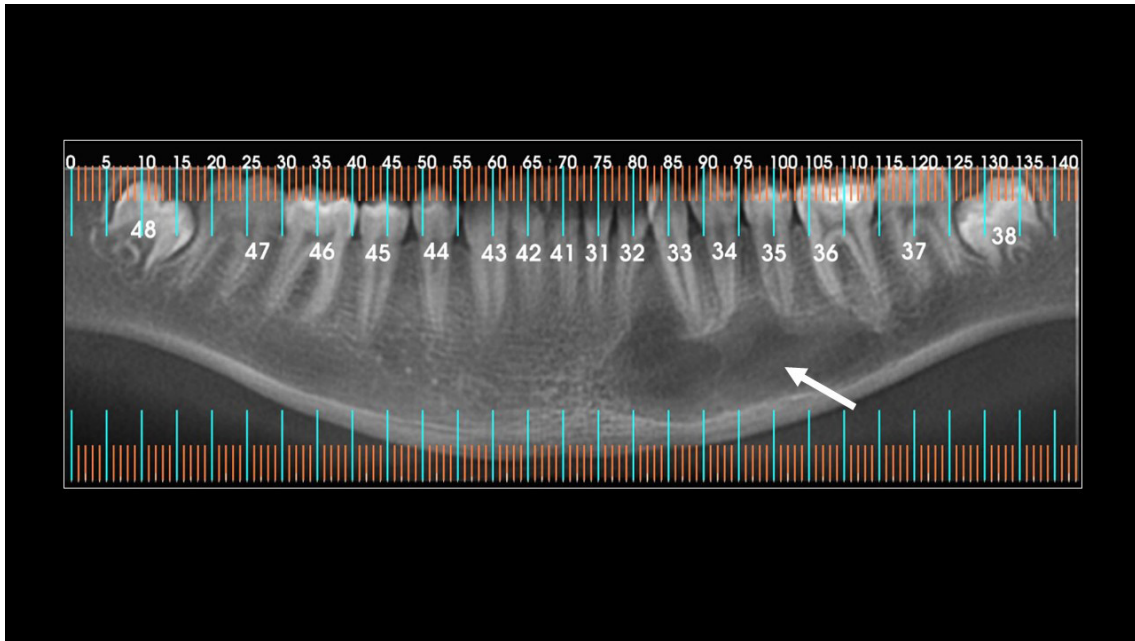


Figure 1 - Panoramic coronal reconstruction evidences a hypodense bone lesion in the left mandibular body (arrow), revealing its extension on mesiodistal and lower-upper directions

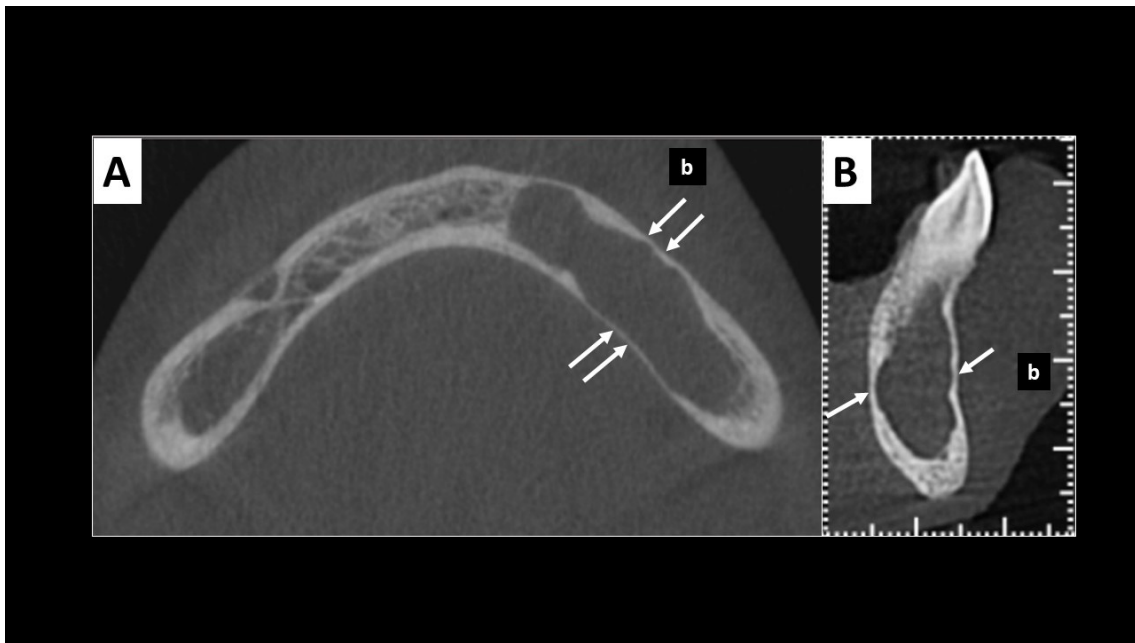


Figure 2 - Axial (A) and cross-sectional (B) images reveal erosion (arrows) and subtle expansion in the buccal and lingual bone cortical (b - buccal bone cortical)

Additionally the following findings were evident in CBCT images: scalloped edges of the lesion (figure 3A), slight external root resorption at the apex of mandibular left second premolar (figure 3B), incomplete septa (figure 3C) and mandibular canal involvement by the lesion (figure 4).

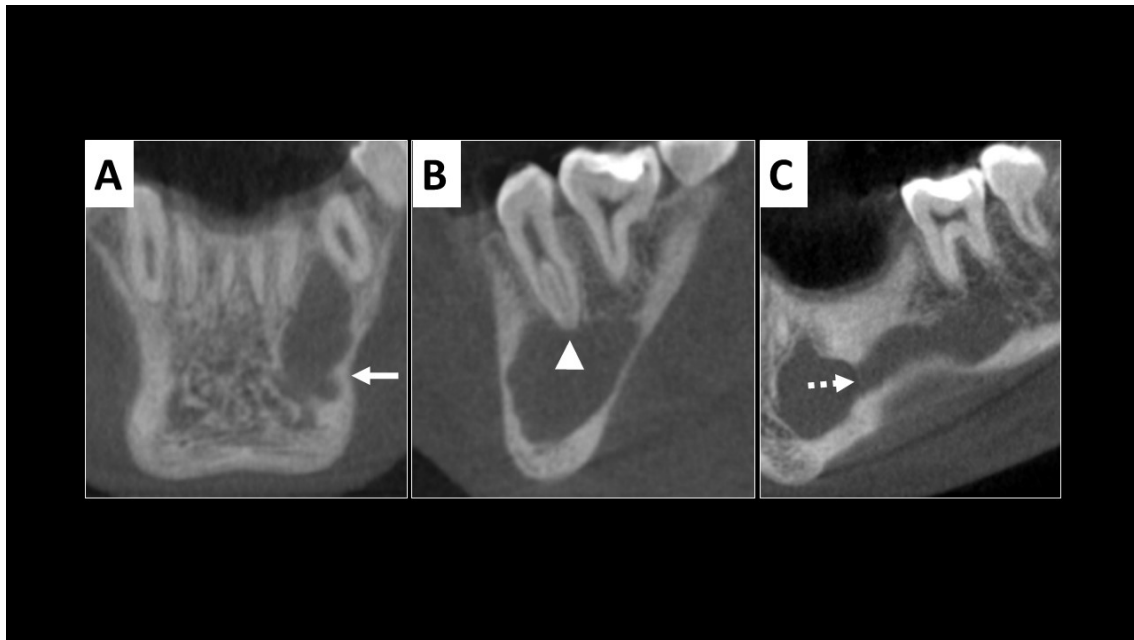


Figure 3 - Coronal image (A) evidences scalloped edges of the lesion (arrow); sagittal image (B) reveals slight external root resorption at the apex of mandibular left second premolar (arrowhead); sagittal image (C) demonstrates subtle incomplete septa (dotted arrow)

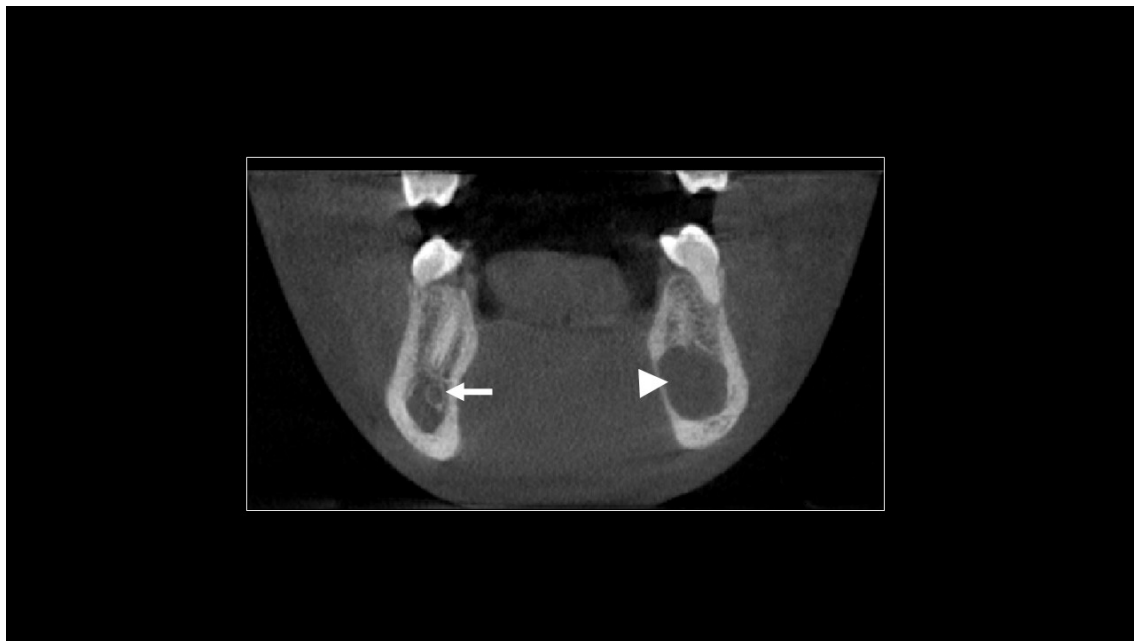


Figure 4 - Coronal image reveals the walls of right mandibular canal (arrow); in the left side, the lesion involved the walls of mandibular canal (arrowhead)

Discussion

In the literature, many studies have investigated particularities on CBCT findings to contribute for bone lesions diagnosis. The study of Alves *et al.* [2] included 9 OKs and 9 ameloblastomas microscopically confirmed and then presented CBCT findings of these lesions. Kitisubkanchana *et al.* [11] carefully evaluated CBCT images of cases histopathologically diagnosed as OK or ameloblastomas. After that, they reported imaging findings suggestive of an OK. Similarly, in the present study, details on CBCT

images were important for analyzing a bone lesion. The sectional images revealed peculiarities which, associated to clinical data, directed to a probable OK diagnosis.

Although final diagnosis of a bone lesion usually depends on a microscopic evaluating, in some instances incisional biopsy could not reveal a definitive diagnosis especially from large lesions or lesions with inflammation. Thus, CBCT findings may play an important role in making the differential diagnosis [11]. Such data reveal the importance of careful analyses of sectional images, as in the present study.

Considering that OK is usually asymptomatic with no or a mild associated bone cortical expansion, the lesion is frequently detected on routine radiographic examinations [4, 6]. Often the OK is an incidental finding on a panoramic radiography because such radiographic examination is widely used in Dentistry [8, 13]. The present study ratifies these data because detection of the probable OK was incidental on a panoramic radiography.

In a systematic review, MacDonald-Jankowski [13] demonstrated that, although there is a higher incidence of OK in individuals aged 30, there are cases in the first and second decade of life. The data from the present case, which involves a 14-year-old patient, corroborate this conclusion.

Regarding tomographic aspect, OK usually appears as a hypodense and unilocular lesion [11, 12, 20]. Alves *et al.* [2] reported that 78% of the OKs included in their study were unilocular. In the study of Sánchez-Burgos *et al.* [16], the prevalence was 71%. Shudou *et al.* [19] detected such evidence on 66% of the cases, while Gumusok *et al.* [8] observed it on 50% of the OKs. Such conclusions of the literature are in accordance to the present study that involves a unilocular and hypodense extensive mandible lesion.

Alves *et al.* [2] concluded that 77% of the OK, 7 of 9 analyzed cases, presented mild bone cortical expansion. Moreover, four cases presented fusiform bone cortical expansion, differing from soap bubble-like expansion that is frequently associated to ameloblastoma. Kitisubkanchana *et al.* [11] and Scarfe *et al.* [18] reported that OKs usually cause minimal bone cortical expansion, growing along the internal aspect of the mandible. In the present case report, there was mild buccal and lingual bone cortical expansion and no lower bone cortical dilatation. Such conclusions corroborate literature findings.

Sectional images can also reveal external root resorption associated to the lesion [11]. In a retrospective study, Gumusok *et al.* [8] analyzed 28 patients presenting an OK, so that associated root resorption was observed in 6 of them (30% of patients). In a comparative study, Alves *et al.* [2] reported root resorption related to 1 of 9 OKs (11% of the cases). Moreover, the authors pointed out that comparing OK to ameloblastoma, the first one usually is associated to less severe root resorption. Thus, the present case report corroborates the literature, presenting a slight external root resorption at the apex of mandibular left second premolar, as shown in figure 3B.

In accordance to Borghesi *et al.* [4], OKs can exhibit partial septa inside radiolucent area, especially in large lesions. Moreover, the same authors reported the following two frequent radiological features of an OK: scalloped edges and erosion of bone cortical. In the present case report, CBCT images revealed such features.

In the study of Gumusok *et al.* [8], 90% of OKs in the jaw induced resorption of mandibular canal walls and 60% caused displacement of this anatomic structure. Similarly, the present study reveals interruption of mandibular canal walls by the lesion, as pointed out in figure 4.

Although clinical and tomographic data directed to the probable diagnosis of an OK, another possibilities must be included in the differential diagnosis. Simple bone cyst must be included because it usually occurs at young patients, in the mandible, without significant bone cortical expansion and presenting scalloped edges. Another possibility is the ameloblastoma, frequently detected at posterior mandible. However, it usually occurs at older age group and causes extensive bone cortical expansion [21].

Conclusion

The peculiarities on CBCT images contributed to suggest a probable OK in the diagnosis of the bone lesion. The scalloped edges of the lesion, mild bone cortical expansion, slight associated root resorption, erosion in bone cortical and partial septa were relevant. The integration of clinical and tomographic findings was essential to contribute for diagnostic process. The sectional images does not substitute microscopic analysis for final diagnosis of the bone lesion.

References

1. Al-Moraissi EA, Pogrel MA, Ellis 3rd E. Enucleation with or without adjuvant therapy versus marsupialization with or without secondary enucleation in the treatment of keratocystic odontogenic tumors: a systematic review and meta-analysis. *J Craniomaxillofac Surg.* 2016;44(9):1395-403.
2. Alves DBM, Tuji FM, Alves FA, Rocha AC, Santos-Silva AR, Vargas PA et al. Evaluation of mandibular odontogenic keratocyst and ameloblastoma by panoramic radiograph and computed tomography. *Dentomaxillofac Radiol.* 2018;47(7):1-7.
3. Bilodeau EA, Collins BM. Odontogenic cysts and neoplasms. *Surg Pathol Clin.* 2017;10:177-222.
4. Borghesi A, Nardi C, Giannitto C, Tironi A, Maroldi R, Bartolomeo FD et al. Odontogenic keratocyst: imaging features of a benign lesion with an aggressive behaviour. *Insights Imaging.* 2018;9(5):883-97.
5. Brannon RB. The odontogenic keratocyst. A clinicopathologic study of 312 cases. Part I. Clinical features. *Oral Surg Oral Med Oral Pathol.* 1976;42(1):54-72.
6. Castro MS, Caixeta CA, de Carli ML, Ribeiro Júnior NV, Miyazawa M, Pereira AAC et al. Conservative surgical treatments for nonsyndromic odontogenic keratocysts: a systematic review and meta-analysis. *Clin Oral Investig.* 2018;22(5):2089-101.
7. Dominguez FV, Keszler A. Comparative study of keratocysts, associated and non-associated with nevoid basal cell carcinoma syndrome. *J Oral Pathol.* 1988;17(1):39-42.
8. Gumusok M, Alkurt MT, Museyibov F, Ucok O. Evaluation of keratocystic odontogenic tumors using cone beam computed tomography. *J Istanbul Univ Fac Dent.* 2016;50(3):32-7.
9. Habibi A, Saghravanian N, Habibi M, Mellati E, Habibi M. Keratocystic odontogenic tumor: a 10-year retrospective study of 83 cases in an Iranian population. *J Oral Sci.* 2007;49(3):229-35.
10. Katz JO, Underhill TE. Multilocular radiolucencies. *Dent Clin North Am.* 1994;38(1):63-81.
11. Kitisubkanchana J, Reduwan NH, Poomsawat S, Pornprasertsuk-Damrongsri S, Wongchuensoontorn C. Odontogenic keratocyst and ameloblastoma: radiographic evaluation. *Oral Radiol.* 2021;37(1):55-65.
12. MacDonald D. Lesions of the jaws presenting as radiolucencies on cone-beam CT. *Clin Radiol.* 2016;71(10):972-85.
13. MacDonald-Jankowski DS. Keratocystic odontogenic tumour: systematic review. *Dentomaxillofac Radiol.* 2011;40(1):1-23.
14. Meara JG, Li KK, Shah SS, Cunningham MJ. Odontogenic keratocysts in the pediatric population. *Arch Otolaryngol Head Neck Surg.* 1996;122(7):725-8.
15. Morgan TA, Burton CC, Qian F. A retrospective review of treatment of the odontogenic keratocyst. *J Oral Maxillofac Surg.* 2005;63(5):635-9.
16. Sánchez-Burgos R, González-Martín-Moro J, Pérez-Fernández E, Burgueño-García M, Clinical B-GM. Clinical, radiological and therapeutic features of keratocystic odontogenic tumours: a study over a decade. *J Clin Exp Dent.* 2014;6:259-64.
17. Sapp JP, Eversole LR, Wysocki GP. Contemporary oral and maxillofacial pathology. 2nd ed. St. Louis: Mosby; 2004.
18. Scarfe WC, Toghiani S, Azevedo B. Imaging of benign odontogenic lesions. *Radiol Clin North Am.* 2018;56(1):45-62.
19. Shudou H, Sasaki M, Yamashiro T, Tsunomachi S, Takenoshita Y, Kubota Y et al. Marsupialisation for keratocystic odontogenic tumours in the mandible: longitudinal image analysis of tumour size using 3D visualised CT scans. *Int J Oral Maxillofac Surg.* 2012;41(3):290-6.
20. Soluk-Tekkeşin M, Wright JM. The World Health Organization classification of odontogenic lesions: a summary of the changes of the 2017 (4th) edition. *Turk Patoloji Derg.* 2017;34(1):1-18.
21. White SC, Pharoah MJ. Oral radiology: principles and interpretation. 5th ed. St. Louis: Mosby; 2004. p. 409-15.
22. Woolgar JA, Rippin JW, Browne RM. The odontogenic keratocyst and its occurrence in the nevoid basal cell carcinoma syndrome. *Oral Surg Oral Med Oral Pathol.* 1987;64:727-30.